

CASE STUDY

An Observed Differential in Cerebral Oxygenation (rSO₂ Values) During a Replacement of Ascending Aortic Aneurysm and Aortic Root

| | |
|----------------------------|---|
| Clinical Setting | Adult Complex Cardiovascular Surgery |
| Location | University Teaching Hospital UK – Department of Cardiothoracic Anesthesia and Surgery |
| Clinician | Dr. Aamer Ahmed FRCA FESC FACC, Consultant Cardiovascular Anesthesiologist |
| Masimo Technologies | O3® Regional Oximetry and SedLine® Brain Function Monitoring |

Case History

A 66-year-old male with several comorbidities – Type II Diabetes, Moderate LV ejection fraction (48%), and mild chronic renal impairment – presented with symptoms of increasing breathlessness. Investigation led to a diagnosis of a dilated aortic root with aortic regurgitation and an ascending aortic aneurysm of 5.1cm that required surgical replacement. As is common in thoracic aortic surgeries, because of changes in cerebral perfusion, regional oximetry and brain function monitoring were used. Masimo's O3 regional oximetry and SedLine brain function monitoring were chosen because both monitors are available in the same platform. At the beginning of anesthesia, O3 was used to record baseline values for cerebral oxygenation (rSO₂) before induction.

Clinical Problem

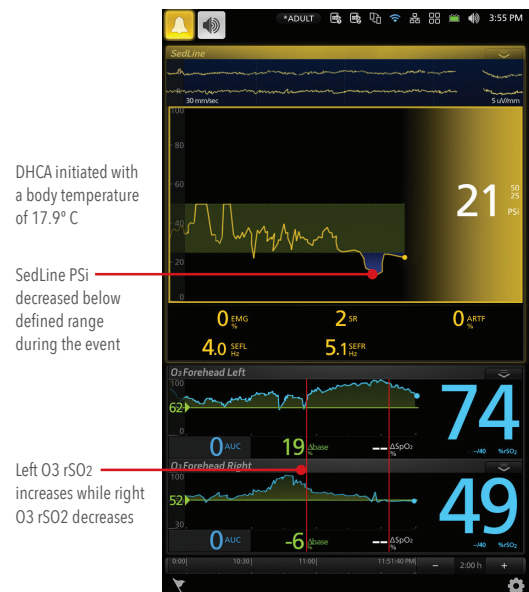
During a replacement of ascending aortic aneurysm and aortic root surgery, normal circulation to the brain is interrupted and antegrade cerebral perfusion instituted, in order to preserve brain perfusion. This involves cardiopulmonary bypass followed by a period of deep hypothermic circulatory arrest (DHCA) whilst the cannulae to the common carotid artery are sited. Once antegrade cerebral perfusion had commenced, Dr. Ahmed used the O3 sensors to enable monitoring of left and right cerebral hemispheres. The left and right channels are usually synchronous and follow similar patterns, which may reflect balanced blood flow between the two sides.

As the surgery progressed, it was noticed that a wide differential had unexpectedly developed between the left and right O3 rSO₂ values. Dr. Ahmed hypothesized that the differential in rSO₂ values indicated that under-perfusion was taking place on one side of the brain. It was also noted that the Patient State Index (PSi) decreased at that time.

The rSO₂ differential was immediately reported to the surgeon for further investigation. The surgeon inspected the position of the cannula and found that it had not been sited where expected. After rapid repositioning of the cannula, there was an upswing in the low rSO₂ value, and the two values returned to normal synchronicity.

Key Takeaway

In this particular case, the Masimo Root with O3 Regional Oximetry was the first monitor to alarm. Dr. Ahmed notes "I find it very useful to be reassured that satisfactory cerebral perfusion is taking place, even if other physiological variables may indicate the same. Given the convenience of having both O3 and SedLine on one monitor, I often use both in my cardiovascular operating room."



DHCA initiated with a body temperature of 17.9° C

SedLine PSi decreased below defined range during the event

Left O3 rSO₂ increases while right O3 rSO₂ decreases

SedLine and O3 Windows on Root®

Caution: Federal (USA) law restricts this device to sale by or on the order of a physician. See instructions for use for full prescribing information, including indications, contraindications, warnings, and precautions.

© 2018 Masimo. All rights reserved.

Masimo U.S.
Tel: 1 877 4 Masimo
info-america@masimo.com

Masimo International
Tel: +41 32 720 1111
info-international@masimo.com

